The diaphragm: revision of the normal anatomy, function and iconographic review of frequent pathology with CT

Poster No.: C-1283

Congress: ECR 2014

Type: Educational Exhibit

Authors: I. Candelaria[1], C. Oliveira[2], H. Donato[1], S. P. F. P. Basso[1], F. Caseiro Alves[1]; [1]Coimbra/PT, [2]Sao Martinho do Bispo/PT

Keywords: Pathology, Hernia, Diagnostic procedure, CT, Conventional radiography, Trauma, Thorax, Anatomy

DOI: 10.1594/ecr2014/C-1283

Learning objectives

Present a simplified revision of the normal anatomy, morphology and function of the diaphragm with CT and conventional radiography

Review and iconographically demonstrate some of the most frequent pathology that can arise or involve the diaphragm.

Background

The diaphragm represents the most important muscle involved in the normal ventilation process, acting also as a physical barrier which separates the thorax from the abdomen.

It can frequently be a cause of dyspnea, due to dysfunction which can be either intrinsic or extrinsic.

Fig. 5
References: Radiology, Centro Hospitalar e Universitario de Coimbra, Hospital Geral - Coimbra/PT
The diaphragm has multiple attachments to the thoracic wall, some of which can be seen with CT, and represents an important landmark for the radiologist.

POSTERIOR ATTACHMENTS

DIAPHRAGMATIC CRURA

They attach the diaphgram to the lumbar vertebral bodies and disks

They are joined by the median arcuate ligament

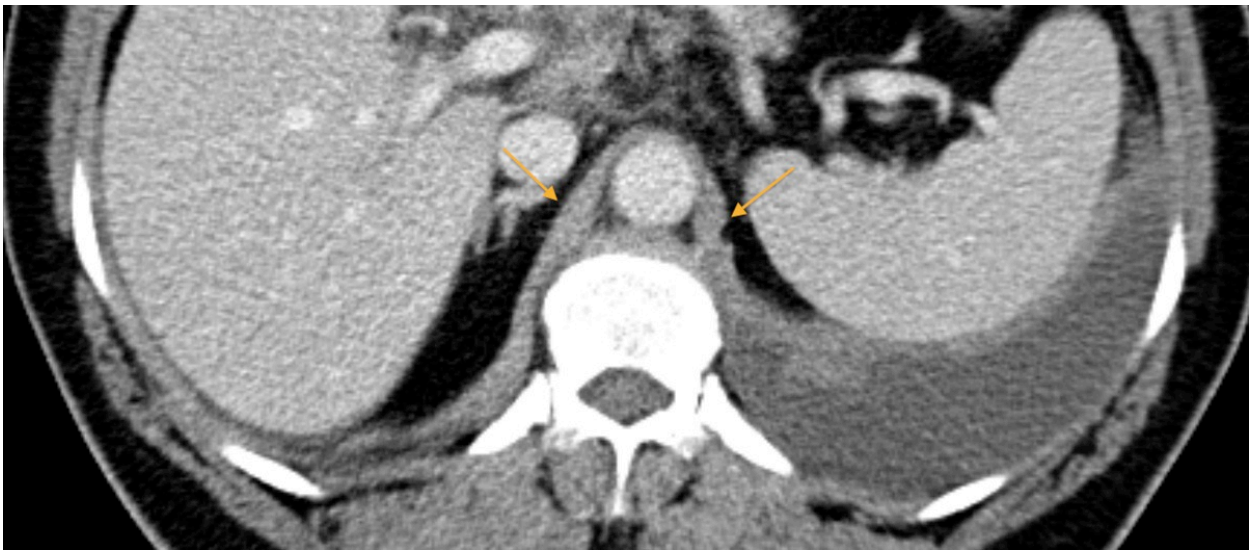

Fig. 6: CT axial image - 53 year-old patient with metastatic melanoma. This image depicts the normal appearance of the diaphragmatic crura, which can either have a smooth of more nodular appearance. Notice also the metastatic implants on the left hemidiaphragm.
References: Radiology, Centro Hospitalar e Universitario de Coimbra, Hospital Geral - Coimbra/PT

MEDIAL AND LATERAL ARCUATE LIGAMENTS

Medial: extends over the anterior psoas muscles as fibrous bands between the L1 or L2 vertebral bodies and transverse process of L1

Lateral: fascial bands that cover the quadratus lumborum muscle and extend from the transverse process of D12 to the middle portion of 12th ribs

ANTERIOR AND LATERAL ATTACHMENTS

They include the sternum (xifoid process), lower six ribs and costal cartilage

These attachments are better depicted with CT

HIATUSES

There are three main hiatuses in the diaphragm which allow the passage of important structures (Fig.2).

1. The inferior vena cava (IVC) hiatus - This hiatus is localized at the D8 level and contains the IVC and branches of the right phrenic nerve. It passes through the midportion of the central tendon and enlarges during inspiration.

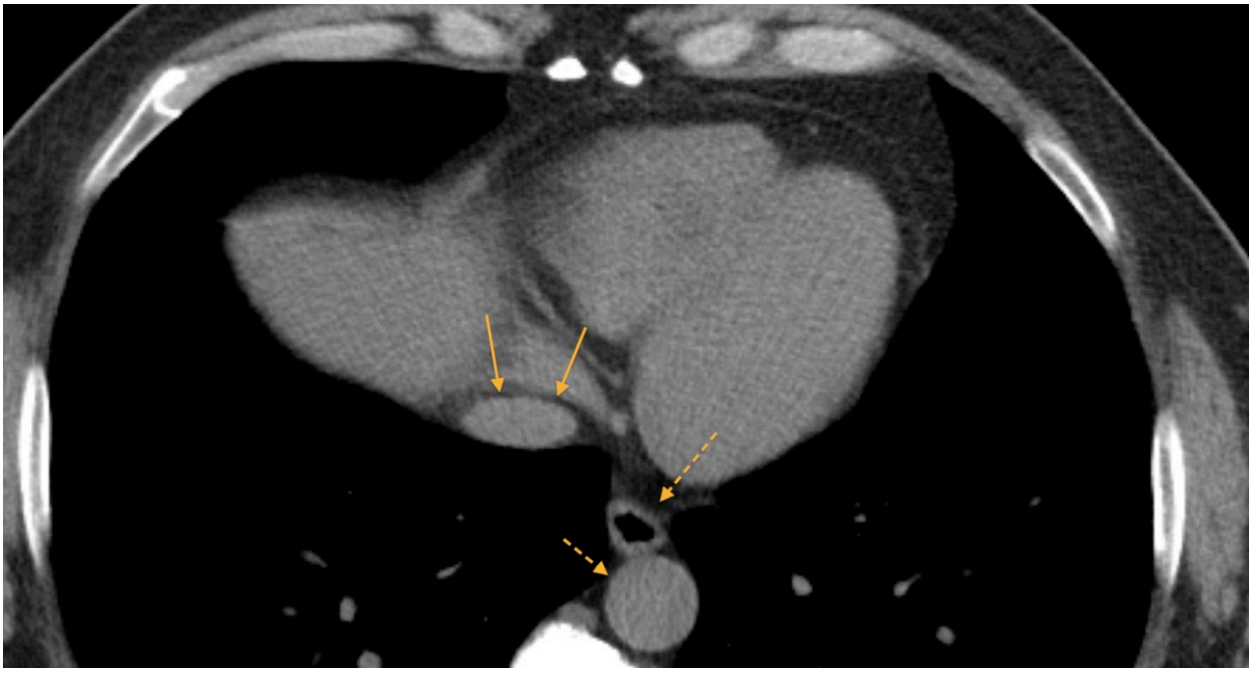

Fig. 7: CT axial image - This image displays the three main diaphragmatic hiatuses, from anterior to posterior: the inferior vena cava hiatus, the esophageal hiatus and the aortic hiatus.
References: Radiology, Centro Hospitalar e Universitario de Coimbra, Hospital Geral - Coimbra/PT

2. The esophagus hiatus - At the level of D10, this hiatus (Fig.8) contains the esophagus, vagus nerve and sympathetic nerve branches. It passes through the crossing fibers of the right diaphragmatic crus, which forms a ring around the esophagus and acts like a sphincter, reducing the occurence of gastroesophageal reflux.

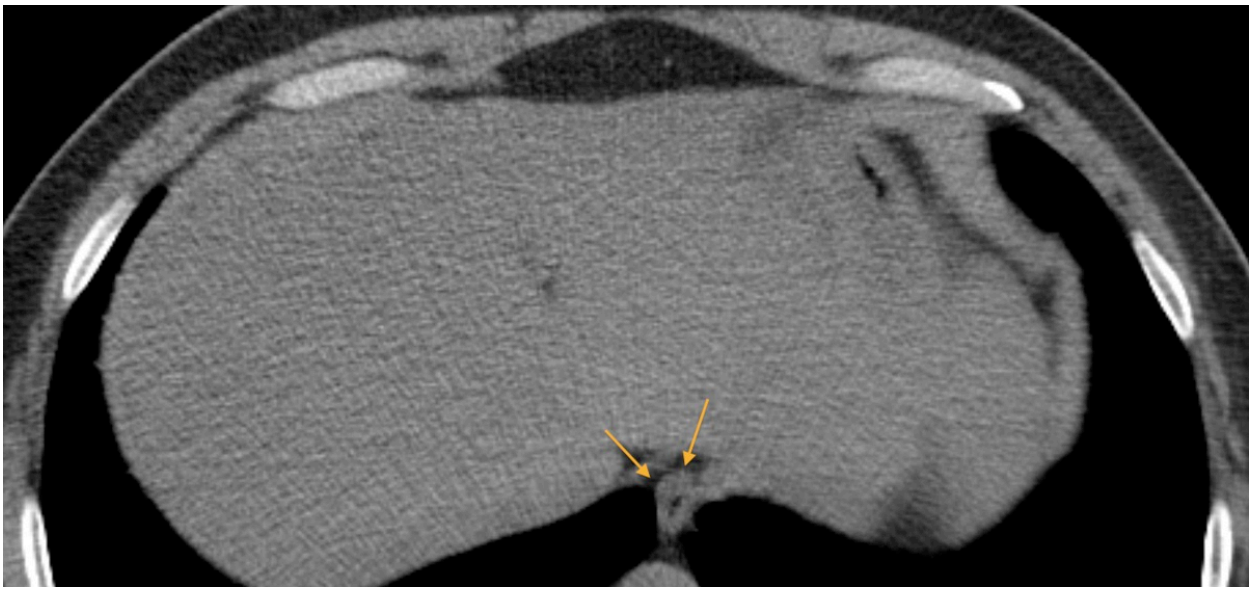

Fig. 8: CT axial image - The esophageal hiatus
References: Radiology, Centro Hospitalar e Universitario de Coimbra, Hospital Geral - Coimbra/PT

3. The aortic hiatus - This hiatus (Fig.9) lies at D12 level, containing the aorta, thoracic duct, azigos and hemiazigos veins. It represents the most retrocrural of all hiatuses.

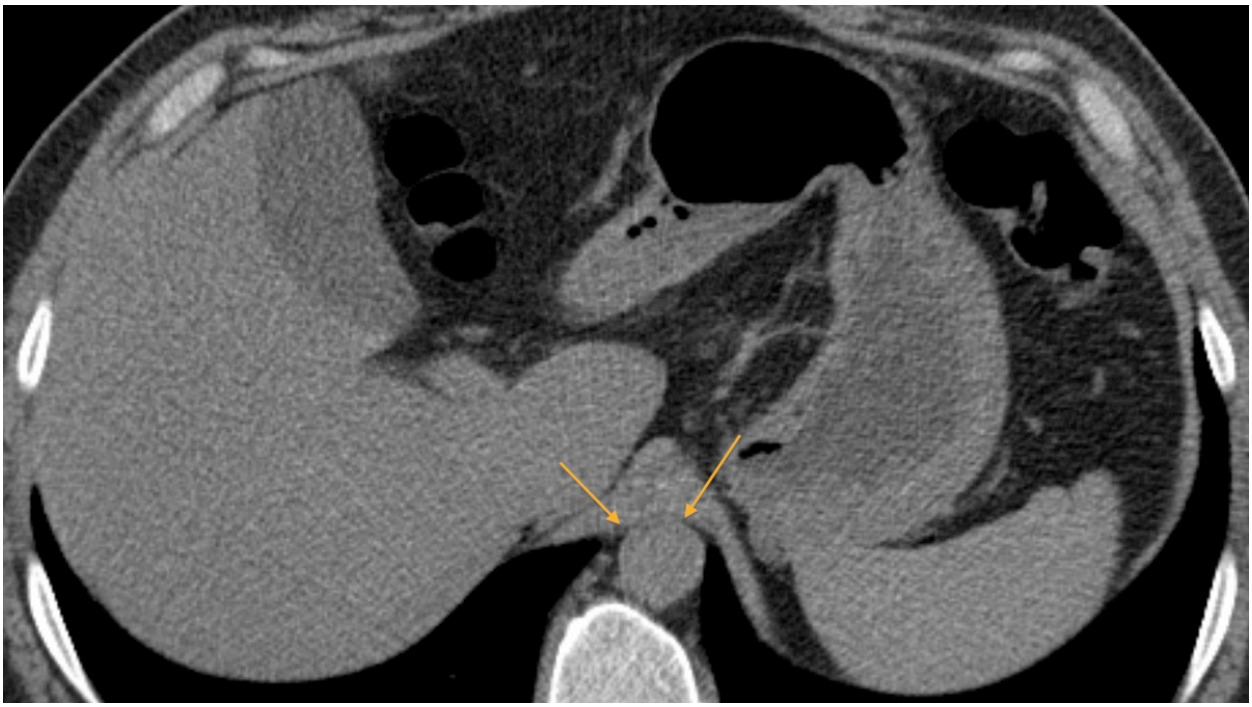

Fig. 9: CT axial image - the aortic hiatus. In this image there is a clear distinction of the diaphragmatic crura and the aorta passing at a posterior level.

References: Radiology, Centro Hospitalar e Universitario de Coimbra, Hospital Geral - Coimbra/PT

Fig. 10
References: Radiology, Centro Hospitalar e Universitario de Coimbra, Hospital Geral - Coimbra/PT

CHEST RADIOGRAPHY

On frontal views (Fig.11), the dome of the right hemidiaphragm is seen at the level of the anterior sixth rib. The left dome is usually one intercostal space lower than the right.

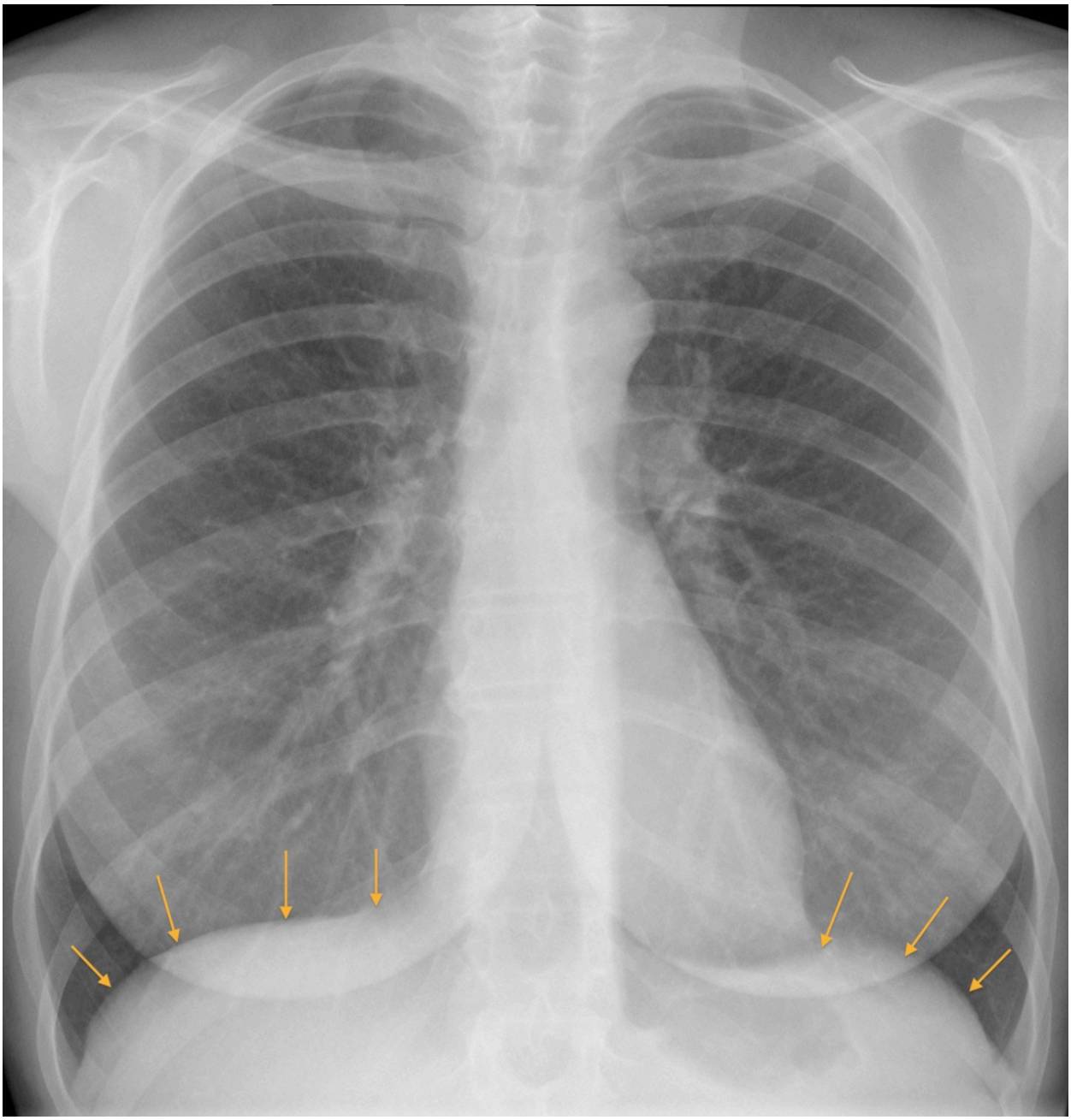

Fig. 11: Chest x-ray PA view. The upper diaphragmatic surface can be easily seen and usually has smooth contours. The right hemidiaphragm can also have a higher position compared to the left, and a difference up to 3cm is still considered normal. ***References:*** Radiology, Centro Hospitalar e Universitario de Coimbra, Hospital Geral - Coimbra/PT

On lateral views, the anterior part of the left dome is obscured by the cardiac shadow but the right dome is entirely seen.

COMPUTED TOMOGRAPHY

With CT, the diaphragm is usually seen as a thin sheeth of muscle which separates the thoracic and abdominal cavities.

There are three typical appearances on axial images:

Type 1 (48%) - the central tendon is cephalic to the xiphoid process. It appears as a ondulating curve of soft tissue, concave posteriorly and continuous across the midline (Fig.12).

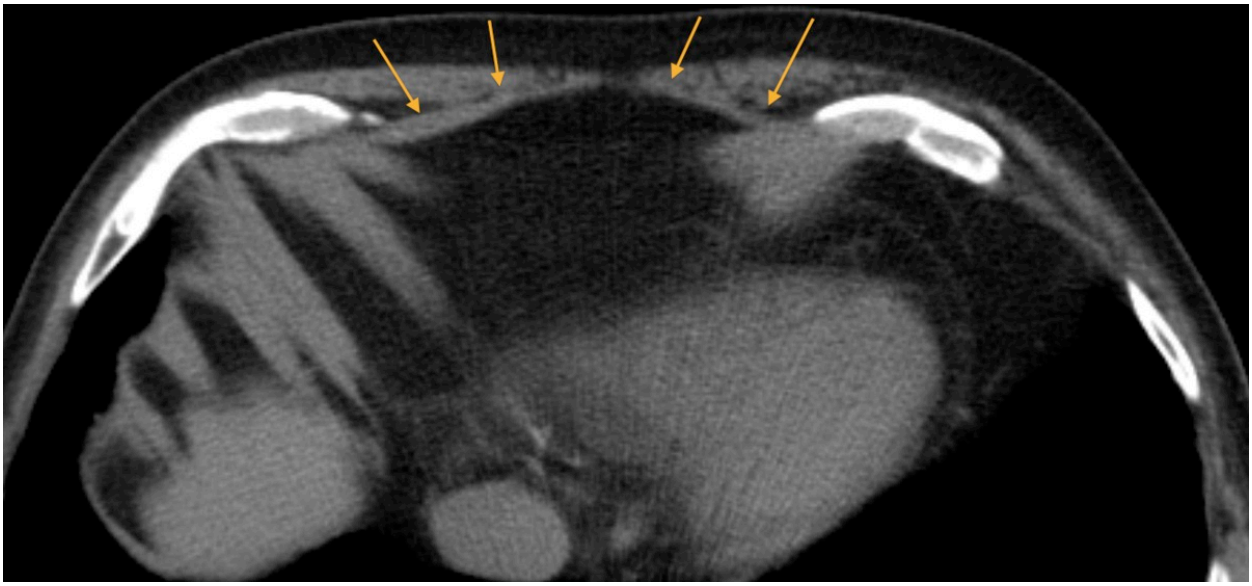

Fig. 12: CT axial slice - Type 1 appearance of the anterior diaphragm.
References: Radiology, Centro Hospitalar e Universitario de Coimbra, Hospital Geral - Coimbra/PT

Type 2 (28%) - the central tendon is caudal to the xiphoid process. The diaphragm has a discontinuous appearance, diverging from the midline as it approaches the anterior thoracic wall.

Type 3 (11%) - the central tendon and the xiphoid process are at the same level. The anterior diaphragm appears as a broad band with irregular and ill defined margins (Fig.13).

Fig. 13: CT axial image - Type 3 appearance of the anterior diaphragm. Notice that the anterior diaphragm is thick and ill defined, as it runs in the same plane of the image.
References: Radiology, Centro Hospitalar e Universitario de Coimbra, Hospital Geral - Coimbra/PT

INNERVATION

Fig. 14
References: Radiology, Centro Hospitalar e Universitario de Coimbra, Hospital Geral - Coimbra/PT

Diaphragmatic innervation is provided by the **right and left phrenic nerves** (Fig.4) (origin at the C3-C5 level), which are fundamental for sensory and motor function.

Location: the phrenic nerves are located at the lateral compartment of the neck and travel anteriorly, coursing through the thorax. They course through the anterior surface of the pericardium, before reaching the diaphragm and branching its superior and inferior surfaces.

NORMAL FUNCTION AND DYSFUNCTION

Fig. 15
References: Radiology, Centro Hospitalar e Universitario de Coimbra, Hospital Geral - Coimbra/PT

The diaphragm is the primary muscle envolved in ventilation. During inspiration it contracts simultaneously with the acessory ventilatory muscles, namely intercostal muscles, sternocleidomastoid and scalene, and expands the thoracic cavity, decreasing intrathoracic pressure and allowing entrance of air.

Diaphragmatic dysfunction can be classified as **paralysis**, **weakness** or **eventration**.

On chest radiography, it can usually be suggested by elevation of the diaphragm, either unilateral or bilateral. It's important to remember that the right dome usually has a higher position than the left dome.

Images for this section:

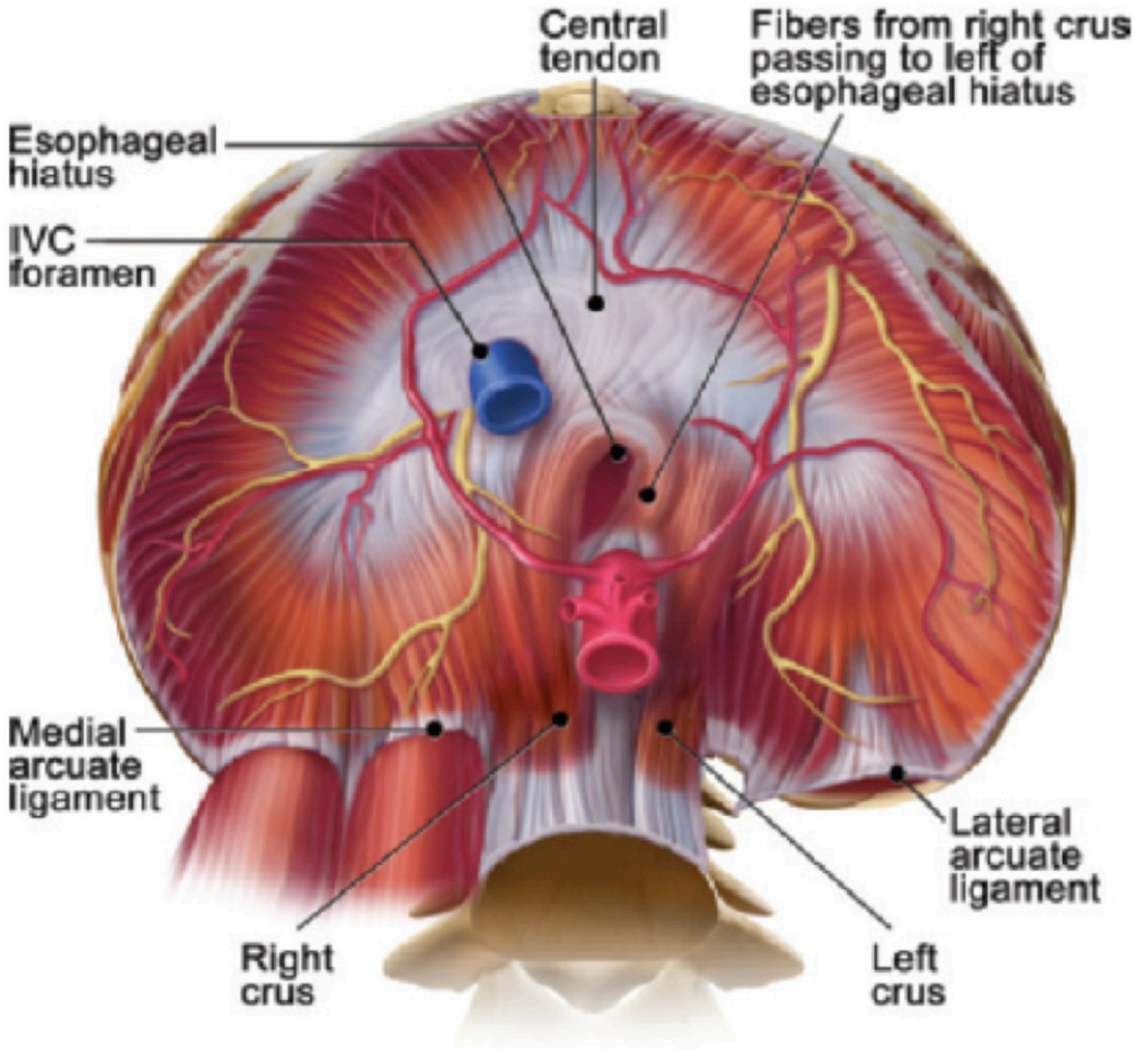

Fig. 1: Schematic representation of the posterior and lateral diaphragmatic attachments to the thoracic wall.

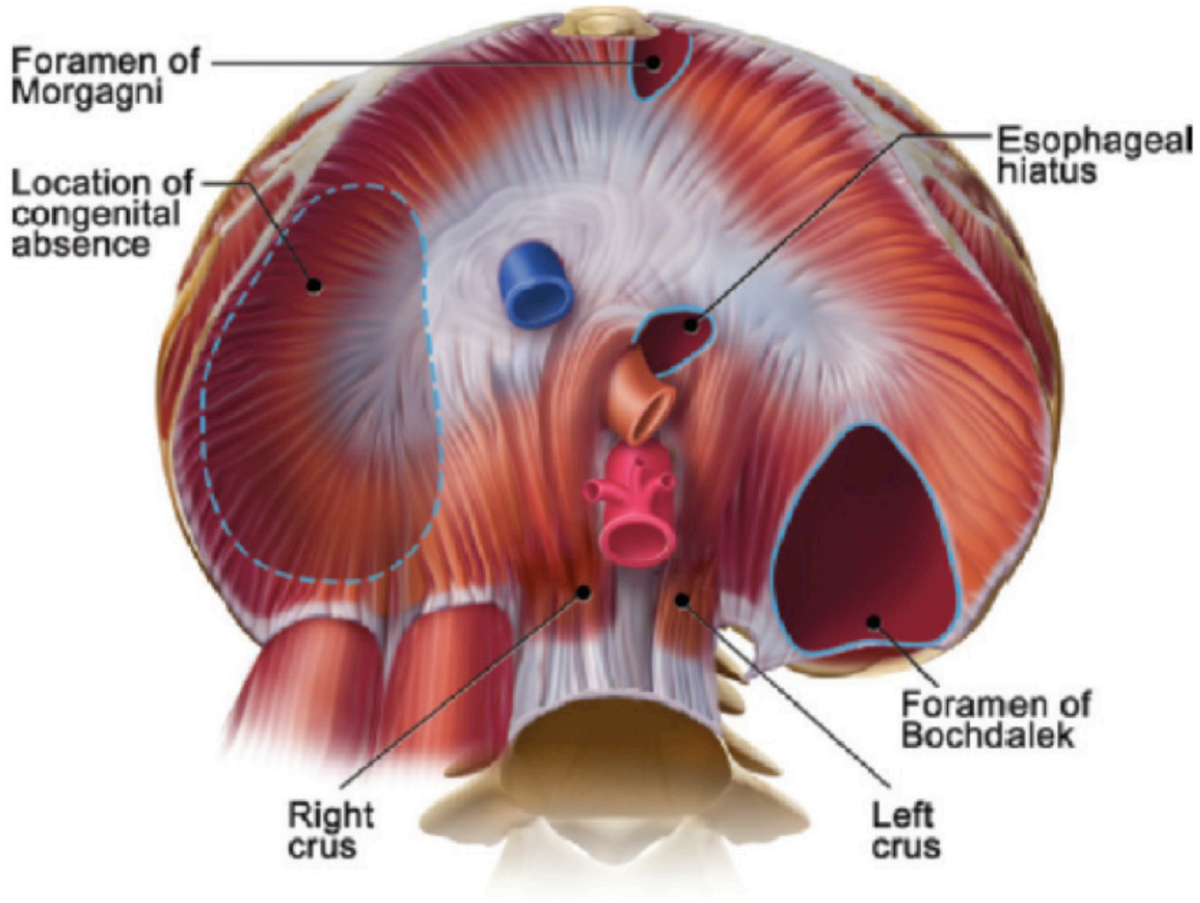

Fig. 2: Illustration which depicts the most frequent locations for diaphragmatic hernias.

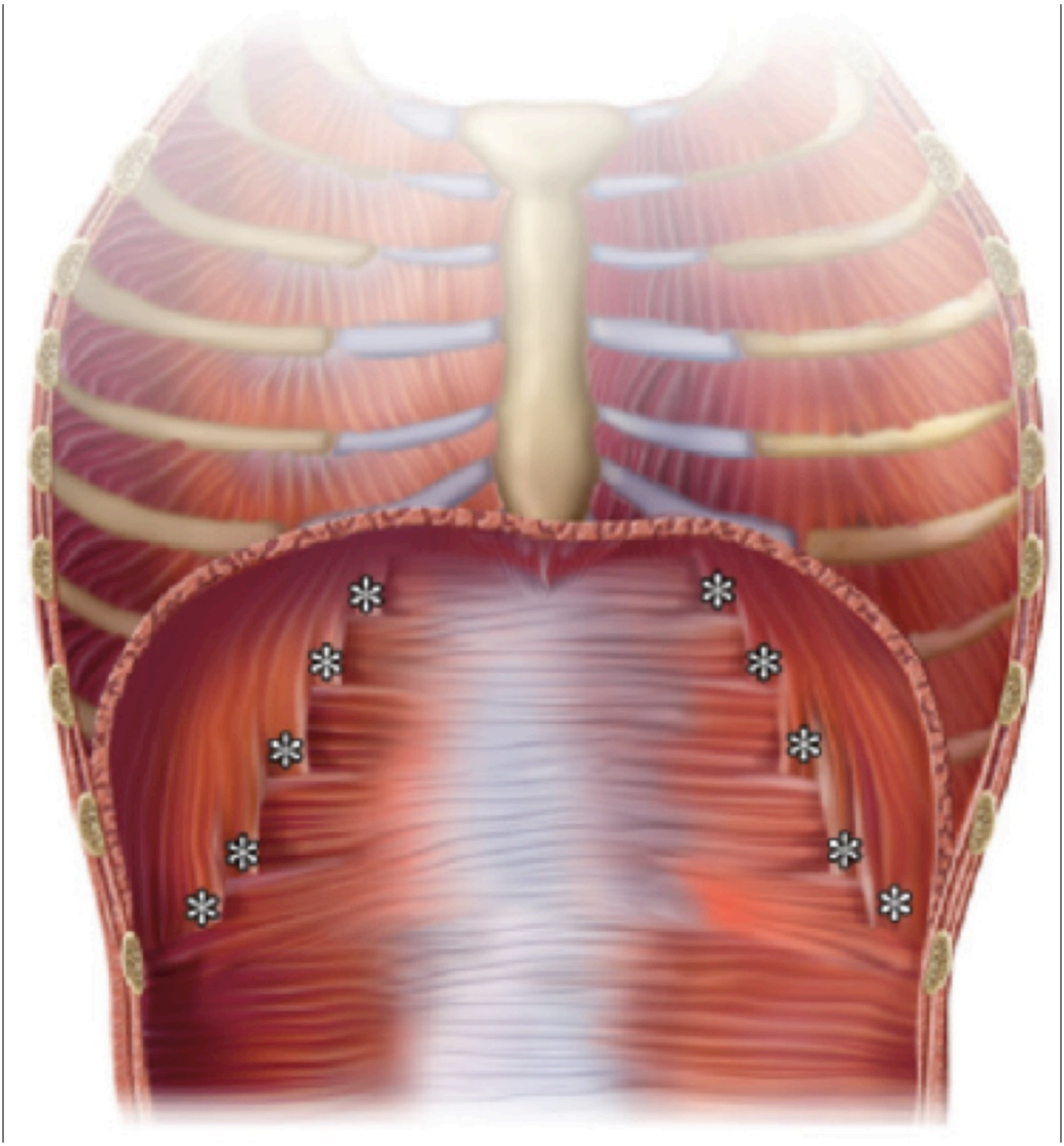

Fig. 3: Schematic representation of diaphragmatic insertions. It depicts the anterior and lateral insertions of the muscle bundles to the lower six ribs.

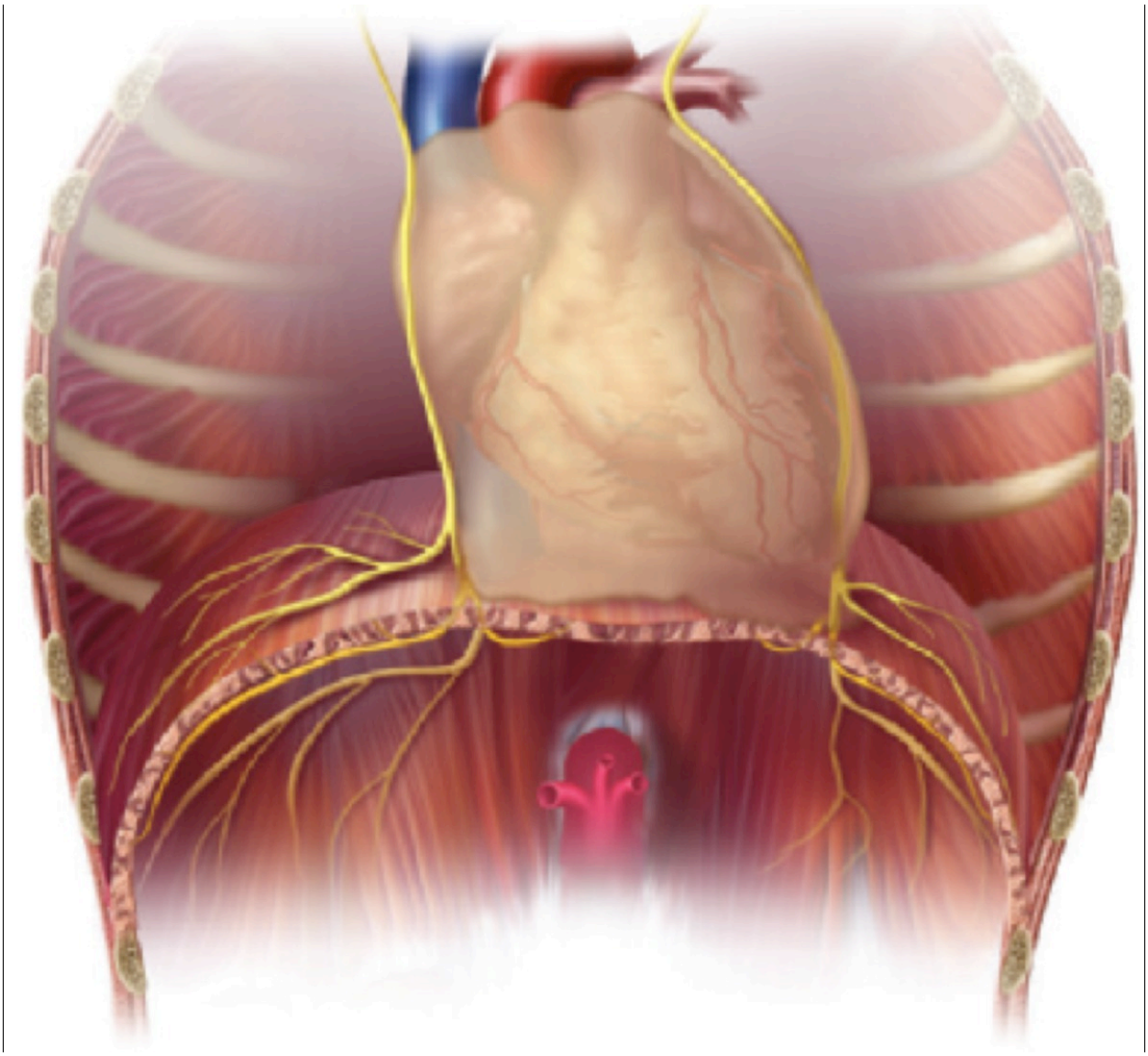

Fig. 4: Schematic representation of diaphragmatic innervation by phrenic nerves. Notice how they reach the superior and inferior surfaces of the diaphragm and form a "branch-like" ramification.

Findings and procedure details

Chest radiography is an important method for evaluating the diaphragm, being the first imaging method which can give information regarding normal positioning and morphological changes, and determining whether or not further evaluation is needed.

CT is, without any doubt, important for a more detailed evaluation of the diaphragm and any underlying condition which can cause changes in its normal position or morphology. It can also help depict with more accuracy the normal anatomy.

This iconographic revision will focus mainly on common diaphragmatic pathology, such as disfunction (eventration), hernias and tumors, which can be adequately seen with chest radiography and characterized with CT.

Fig. 18
References: Radiology, Centro Hospitalar e Universitario de Coimbra, Hospital Geral - Coimbra/PT
EVENTRATION

It represents a congenital thinning of the diaphragm, which leads to a focal bulge. It usually only envolves a segment of the diaphragmatic dome, frequently the anteromedial portion of the right dome. It can become more pronounced with increased intra-abdominal pressure.

On chest radiography, a portion of the hemidiaphragm is elevated, while the rest remains at normal height.

At CT, there's a sharp transition between the edges of the eventration.

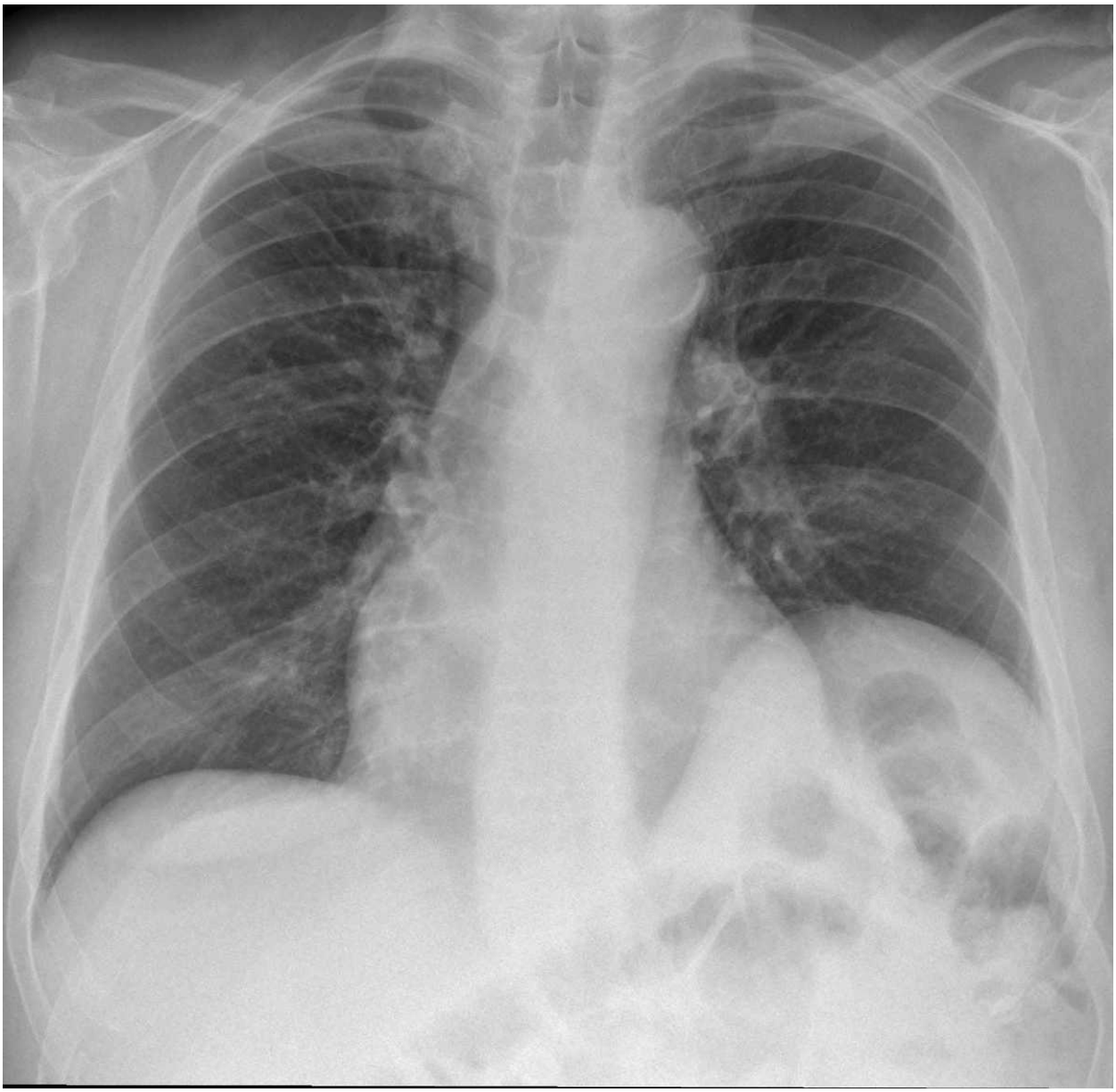

Fig. 19: Chest Radiography PA view - Eventration. 54 year-old male patient with a focal elevation of the left diaphragmatic dome. This patient had a know history of cirrhosis and ascites.
References: Radiology, Centro Hospitalar e Universitario de Coimbra, Hospital Geral - Coimbra/PT

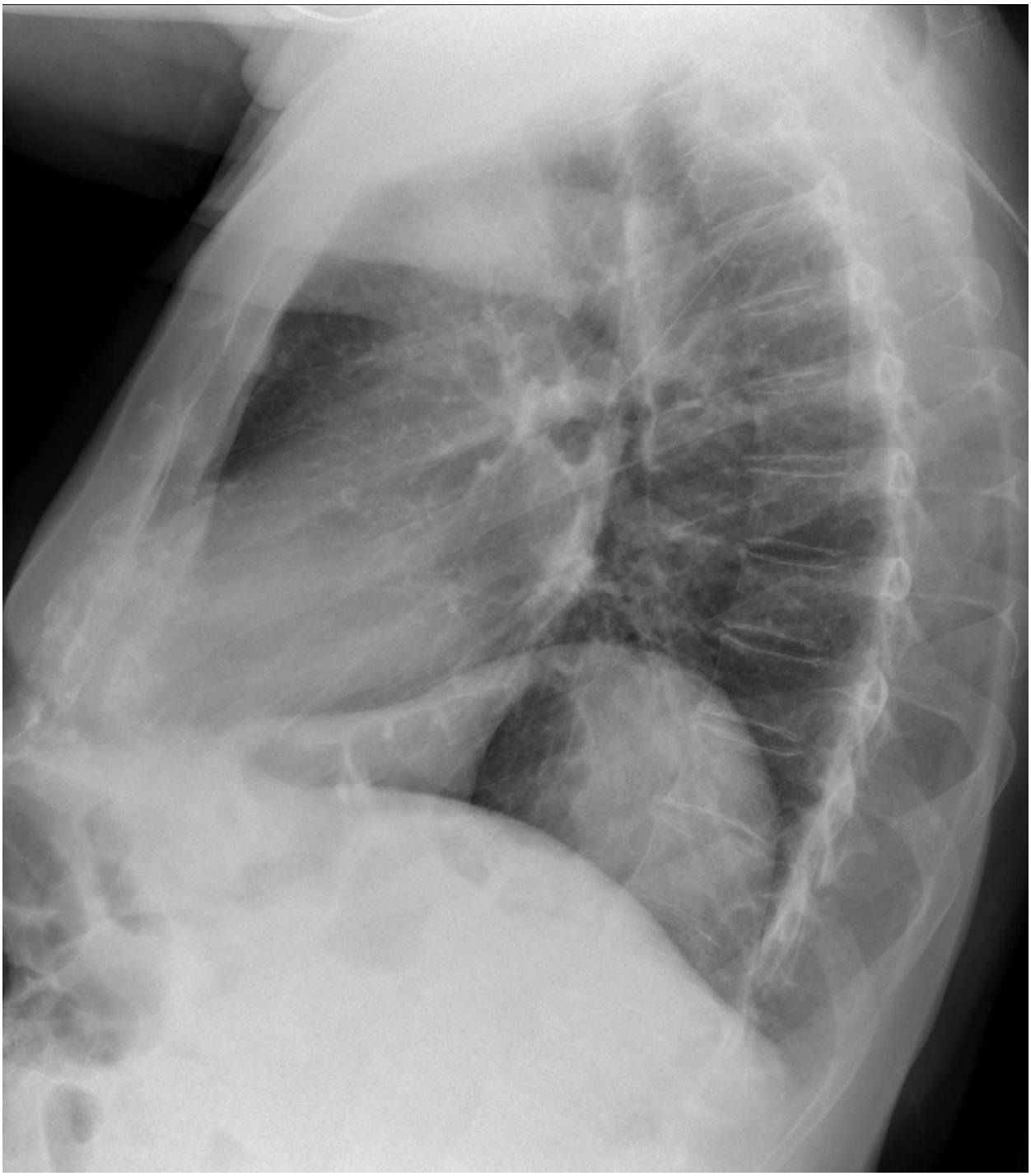

Fig. 20: Chest Radiography lateral view - Eventration. 54 year-old male patient with a focal elevation of the left diaphragmatic dome. This patient had a know history of cirrhosis and ascites.
References: Radiology, Centro Hospitalar e Universitario de Coimbra, Hospital Geral - Coimbra/PT

Fig. 21: CT coronal image - Eventration. 65 year-old patient who underwent CT for staging of colon cancer. Notice the right dome in an elevated position and the focal thinning of the hemidiaphragm in the antero-medial portion of the dome.
References: Radiology, Centro Hospitalar e Universitario de Coimbra, Hospital Geral - Coimbra/PT

PARALYSIS AND WEAKNESS

There are many causes of paralysis and weakness of the diaphragm (Fig.16 - table PW), which can be temporary of permanent depending on the cause. Some can envolve the entire neuromuscular axis.

Phrenic nerve dysfunction is probably one of the most frequent causes of diaphragmatic paralysis or weakness encountered by the radiologist. There are a multitude of causes

for this impairment, such as cardiac surgery, radiation therapy, tumors and neuropathies (Lyme's disease, Guillain-Barré).

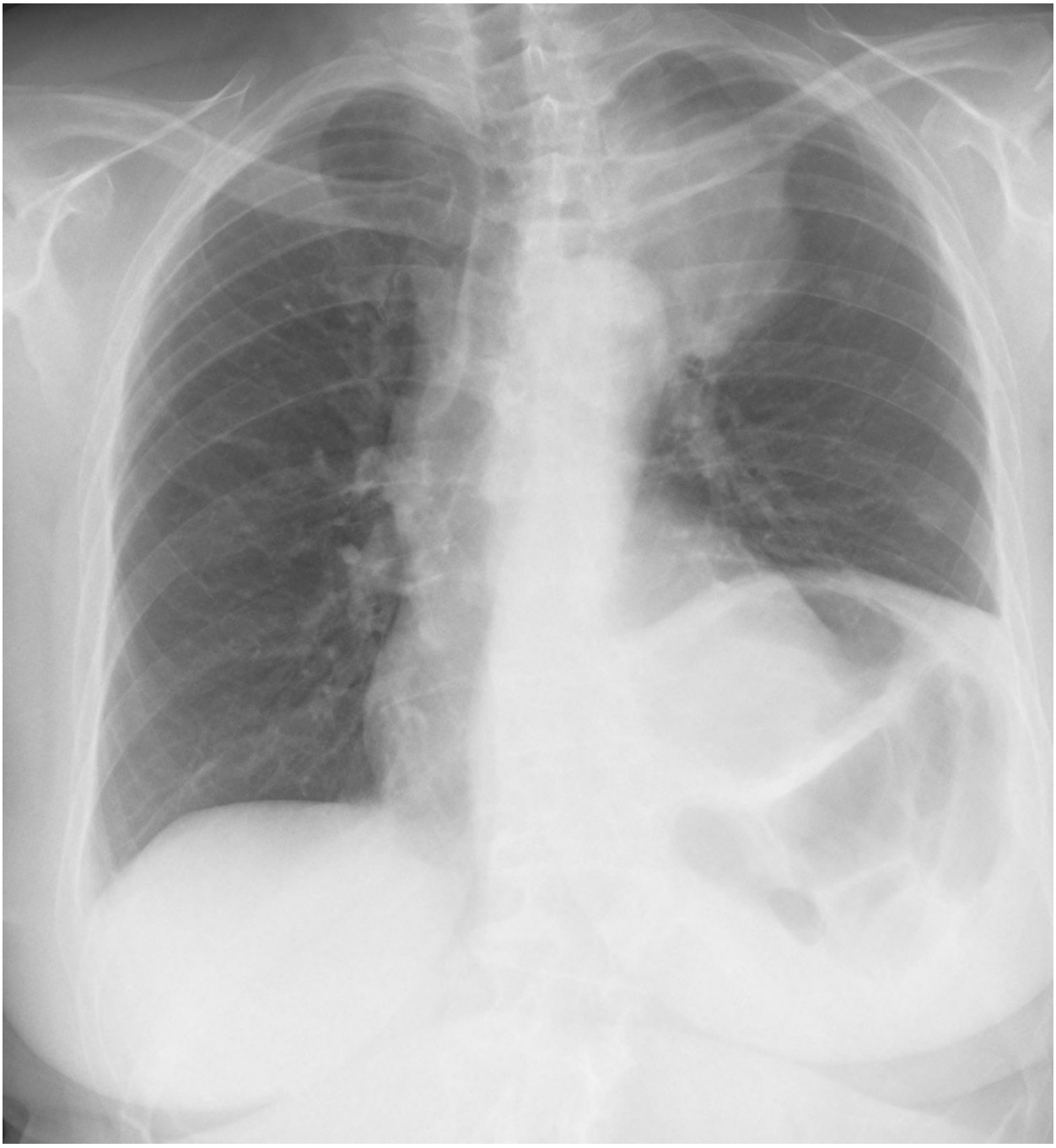

Fig. 22: Chest Radiography PA view - 62 year-old female patient with lung cancer. Notice the left apical pulmonary mass and ipsilateral elevation of the left diaphragmatic dome, secondary to invasion and paralysis of the left phrenic nerve.
References: Radiology, Centro Hospitalar e Universitario de Coimbra, Hospital Geral - Coimbra/PT

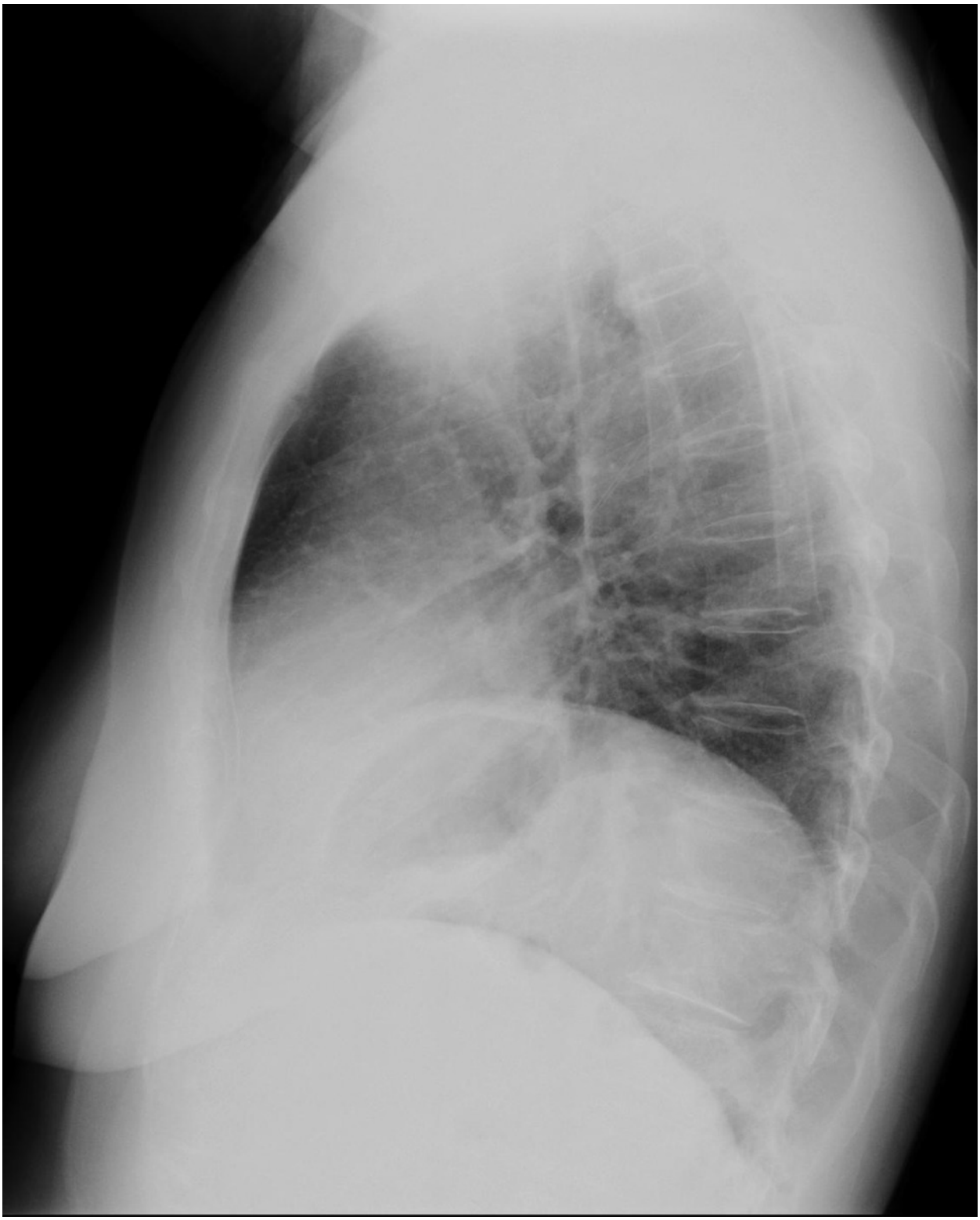

Fig. 23: Chest Radiography lateral view - 62 year-old female patient with lung cancer. There's a continuous elevation of the left diaphragmatic dome, with no focal bulging, secondary to invasion and paralysis of the left phrenic nerve.

References: Radiology, Centro Hospitalar e Universitario de Coimbra, Hospital Geral - Coimbra/PT

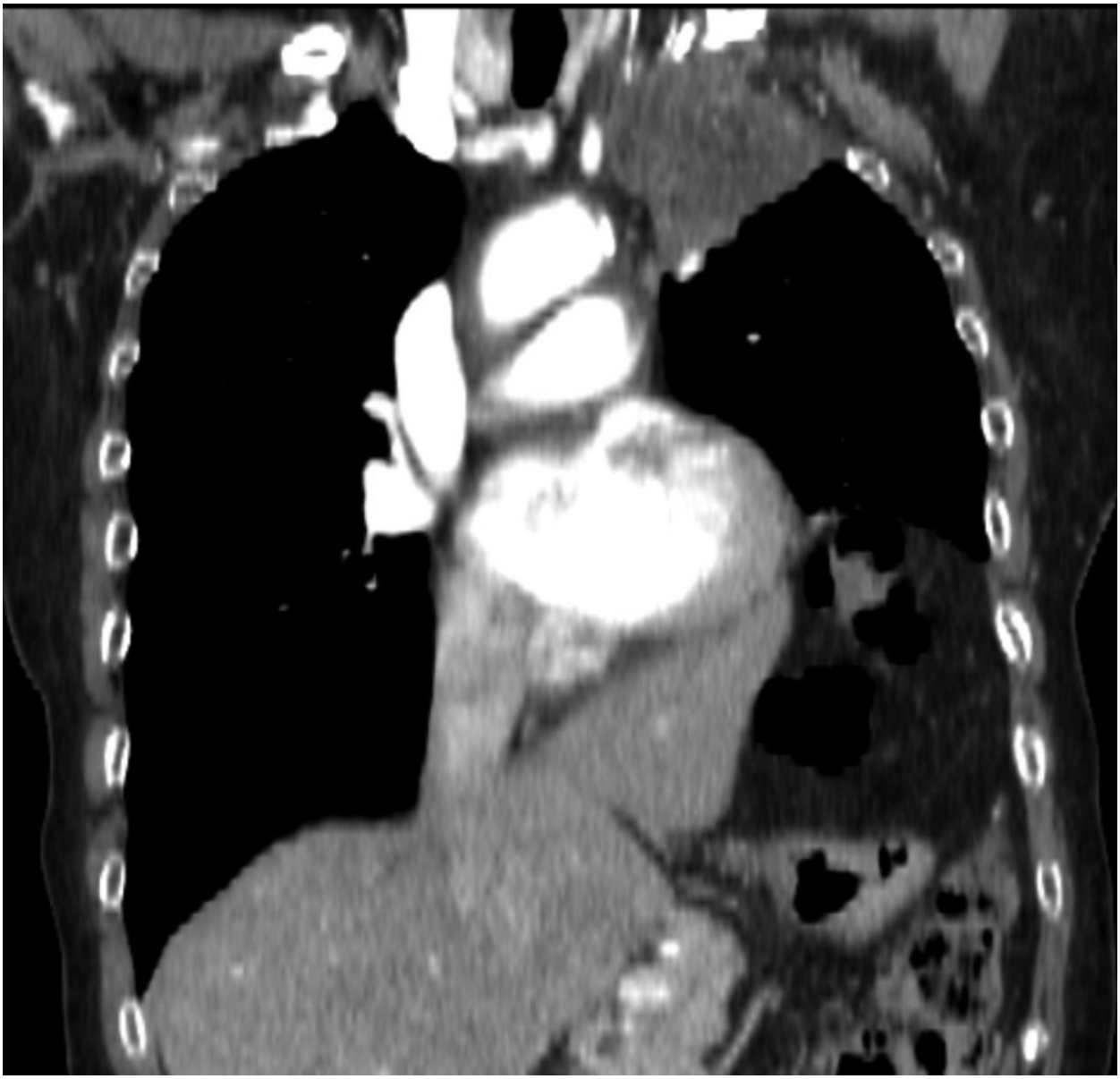

Fig. 24: CT coronal image - 62 year-old female patient with lung cancer. There's no clear plane between the pulmonary mass and the anterior thoracic wall and first rib, which suggests invasion of these structures.
References: Radiology, Centro Hospitalar e Universitario de Coimbra, Hospital Geral - Coimbra/PT

DIAPHRAGMATIC HERNIAS

Fig. 25
References: Radiology, Centro Hospitalar e Universitario de Coimbra, Hospital Geral - Coimbra/PT
HIATAL

Hiatal hernias correspond to herniation of a portion of the stomach into the mediastinum, through the esophageal hiatus.

There are essentially three types of hiatal hernias:

1)sliding hernia - the gastroesophageal junction and part of the stomach move into the thorax through and enlarged foramen.

2)paraesophageal hernia - the gastroesophageal junction remains in its normal position and a portion of the stomach herniates through the esophageal hiatus, in an anterior position

3) congenital short esophagus - the stomach has a fixed position inside the thorax. This type of hernia is more frequent in children.

Paraesophageal hernias are more prone to complications, such as organoaxial volvulus of the stomach and colonic herniation. Although most are congenital, they can also be aquired, namely after Nissen fundaplication.

Fig. 26: Chest radiography PA view - 40 year-old male patient with complaints of gastroesophageal reflux and halitosis. Notice the air-fluid level projected at the cardiac silhouette and the absence of gastric bubble. These findings are compatible with a hiatal hernia.
References: Radiology, Centro Hospitalar e Universitario de Coimbra, Hospital Geral - Coimbra/PT

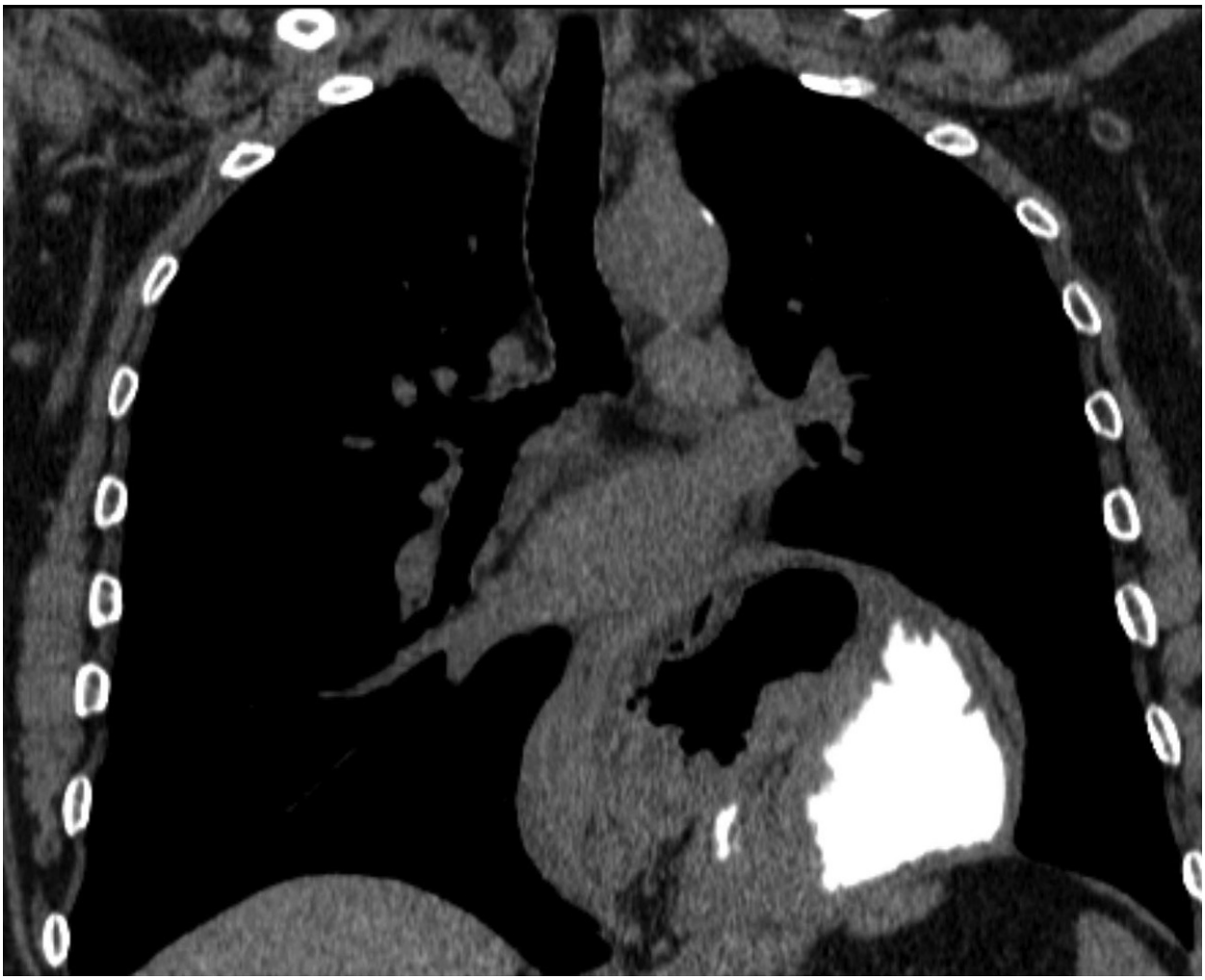

Fig. 27: CT coronal image - Hiatal hernia. Same patient as above. The MPR clearly depicts the gastroesophageal transition in the thorax and there is oral contrast within the herniated stomach.
References: Radiology, Centro Hospitalar e Universitario de Coimbra, Hospital Geral - Coimbra/PT

MORGAGNI

The foramen of Morgagni (Fig.1 and Fig.2) is an anterior opening in the diaphragm, which extends between the sternum medially and the 8th rib laterally. Hernias occuring at this level are mostly unilateral and as much as 90% are **right-sided**. In adulthood, they can be an incidental finding after GI tract obstruction of pulmonary infection.

The most frequent finding on chest radiography is herniated bowel loops on a lateral view. Other viscera can also herniate through the foramen of Morgagni, such as liver, spleen and omentum, and CT is the preferred method of evaluation in these cases.

Fig. 28: Chest radiography PA view - 52 year-old female with incidintal finding of heterogeneous opacity, with some central foci of air, which occupies the lower right hemithorax. The patient underwent CT which demonstrated herniated bowel and omentum, findings compatible with Morgagni hernia.
References: Radiology, Centro Hospitalar e Universitario de Coimbra, Hospital Geral - Coimbra/PT

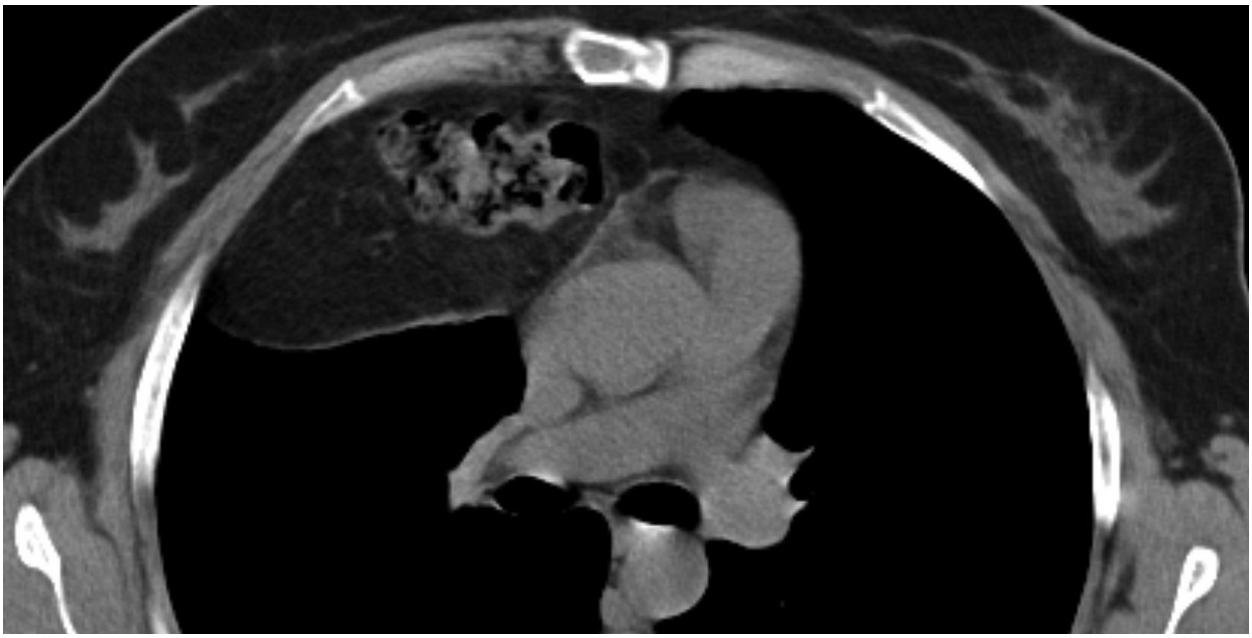

Fig. 29: CT axial image - Same patient as above. Notice the herniated colon and omentum. This is a typical finding for Morgagni hernias.
References: Radiology, Centro Hospitalar e Universitario de Coimbra, Hospital Geral - Coimbra/PT

BOCHDALEK

This is a congenital hernia that occurs through a posterolateral defect in the diaphragm. It is thought to arise from a malformation of the pleuroperitoneal fold or delay in the fusion of the pleuroperitoneal fold and transverse septum.

Most Bochdalek hernias are diagnosed in the antenatal period, with a smaller number of patients manifesting respiratory distress after birth or being completelly assymptomatic in adulthood.

As much as 80% occur on the left side.

Associated anomalies are frequent in patients with Bochdalek hernias, such as cardiovascular anomalies (ventricular or atrial septal defects, Fallot tetralogy), central nervous system defects and miscellanous conditions (cryptorchidism and cleft palate).

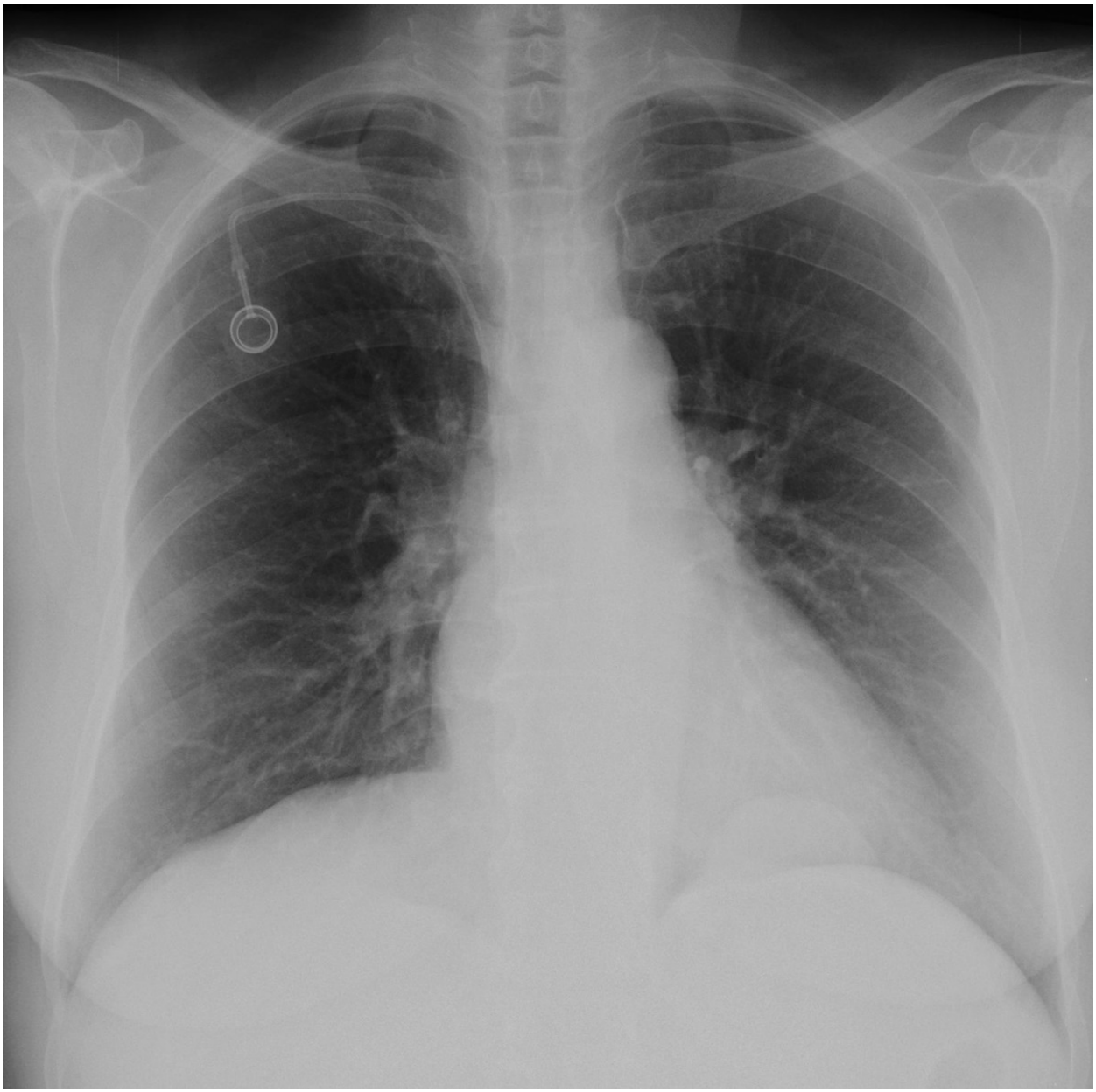

Fig. 30: Chest radiography PA view - 46 year-old female patient with breast cancer. The patient had complaints of dyspnea and there is an incidental finding of a homogeneous oval opacity in the lower and posterior left hemithorax. The patient underwent CT which revealed herniated fat in a small Bochdalek hernia.
References: Radiology, Centro Hospitalar e Universitario de Coimbra, Hospital Geral - Coimbra/PT

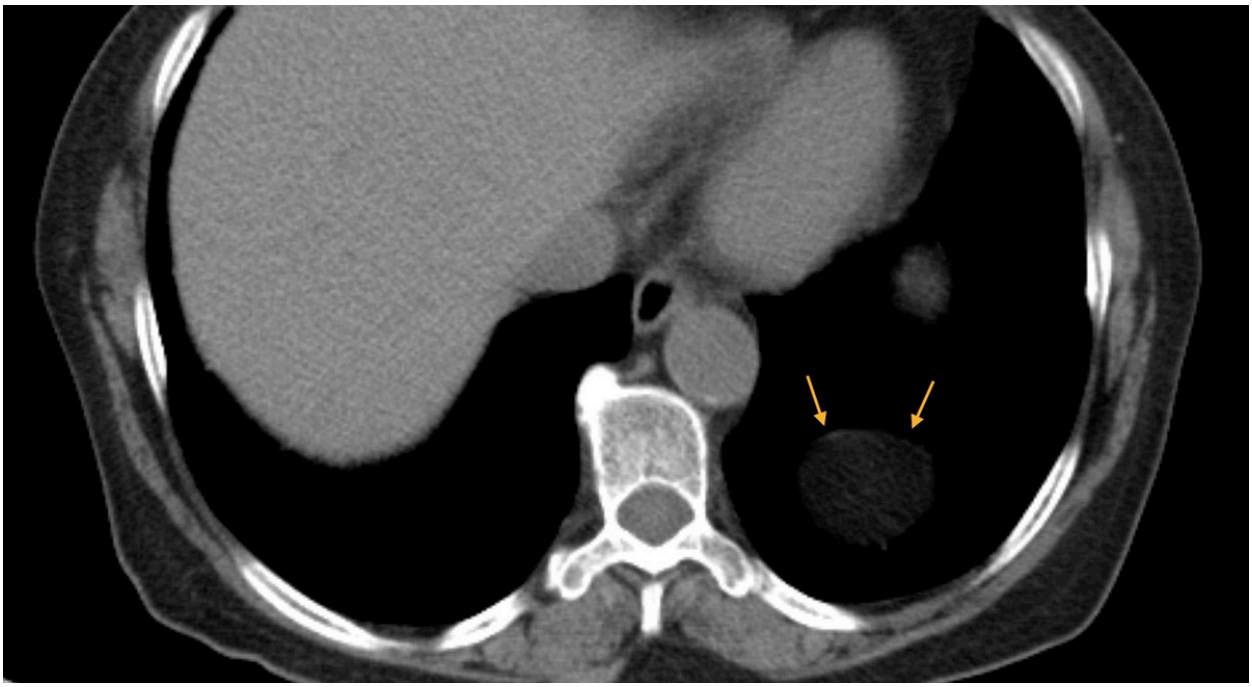

Fig. 31: CT axial image - Bochdalek hernia. Same patient as above. There is a small herniation of fat through a posterolateral defect in the left hemidiaphragm.
References: Radiology, Centro Hospitalar e Universitario de Coimbra, Hospital Geral - Coimbra/PT

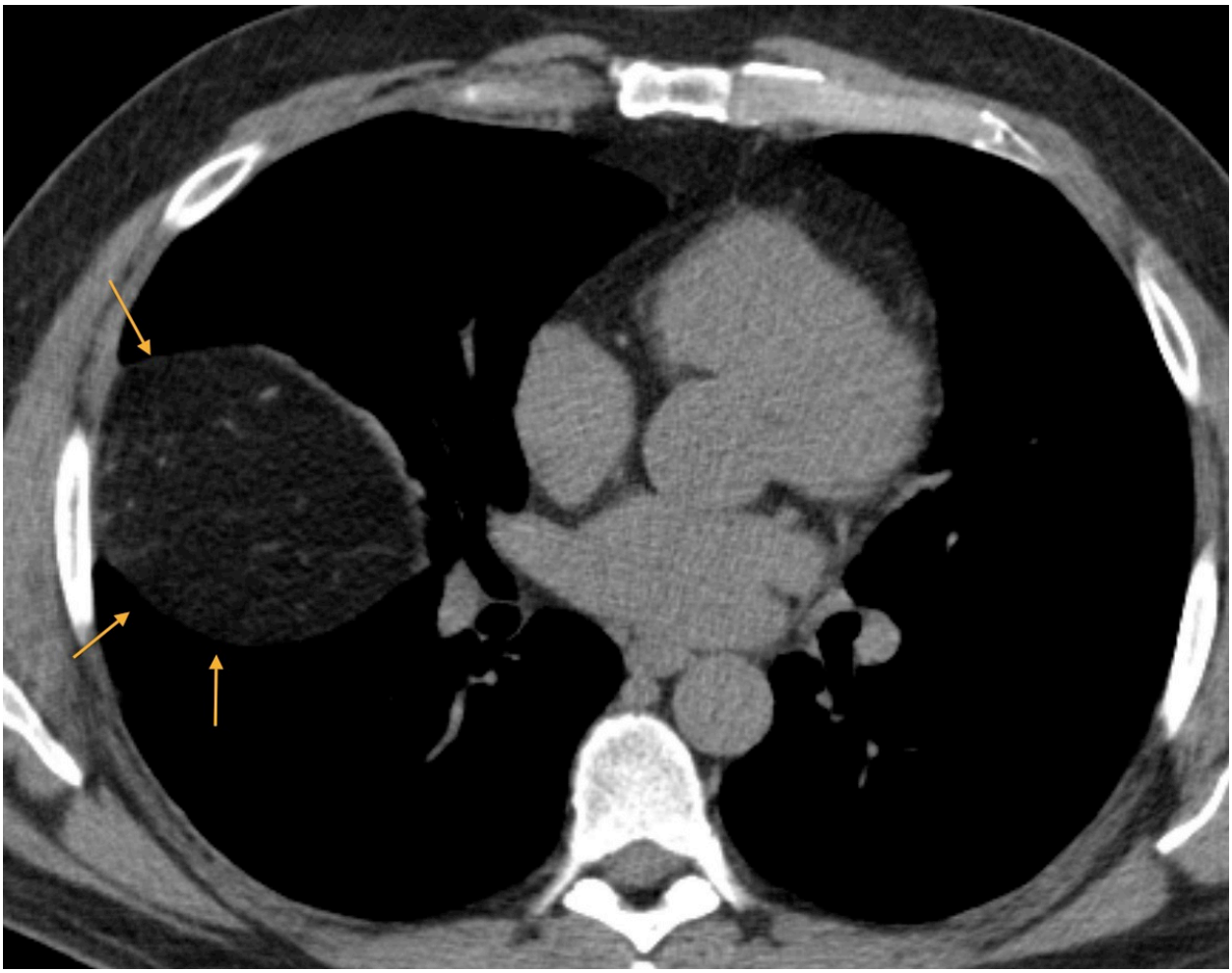

Fig. 32: CT axial image - Right Bochdalek hernia. Although more frequent on the right, as much as 20% of these hernias occur at the right hemidiaphragm.
References: Radiology, Centro Hospitalar e Universitario de Coimbra, Hospital Geral - Coimbra/PT

DIAPHRAGMATIC TUMORS

Fig. 33
References: Radiology, Centro Hospitalar e Universitario de Coimbra, Hospital Geral - Coimbra/PT
Diaphragmatic tumors are uncommon, with scarse cases reported in the literature. They occur with the same frequency in both men and women and exhibit the same prevalence in either right or left diaphragmatic leaflets.

When symptomatic, there are more frequently associated with thoracic rather than abdominal symptoms, namely dyspnea.

PRIMARY TUMORS

Primary diaphragmatic tumors are usually seen in a pediatric population, and are malignant in 78% of the cases, with rhabdomyosarcoma being the most frequent.

Other malignant tumors reported in the diaphgram are undifferentiated sarcomas and Ewing sarcoma and germ cell tumors in children.

Benign lesions can also be seen and the most frequent are lymphangiomas, hemangiomas, lipomas and myofibromas.

Cystic lesions are also uncommon and, as primary tumors, they're more frequent in children. The most frequently described lesions are mesothelial cysts, bronchogenic cysts and cystic teratoma.

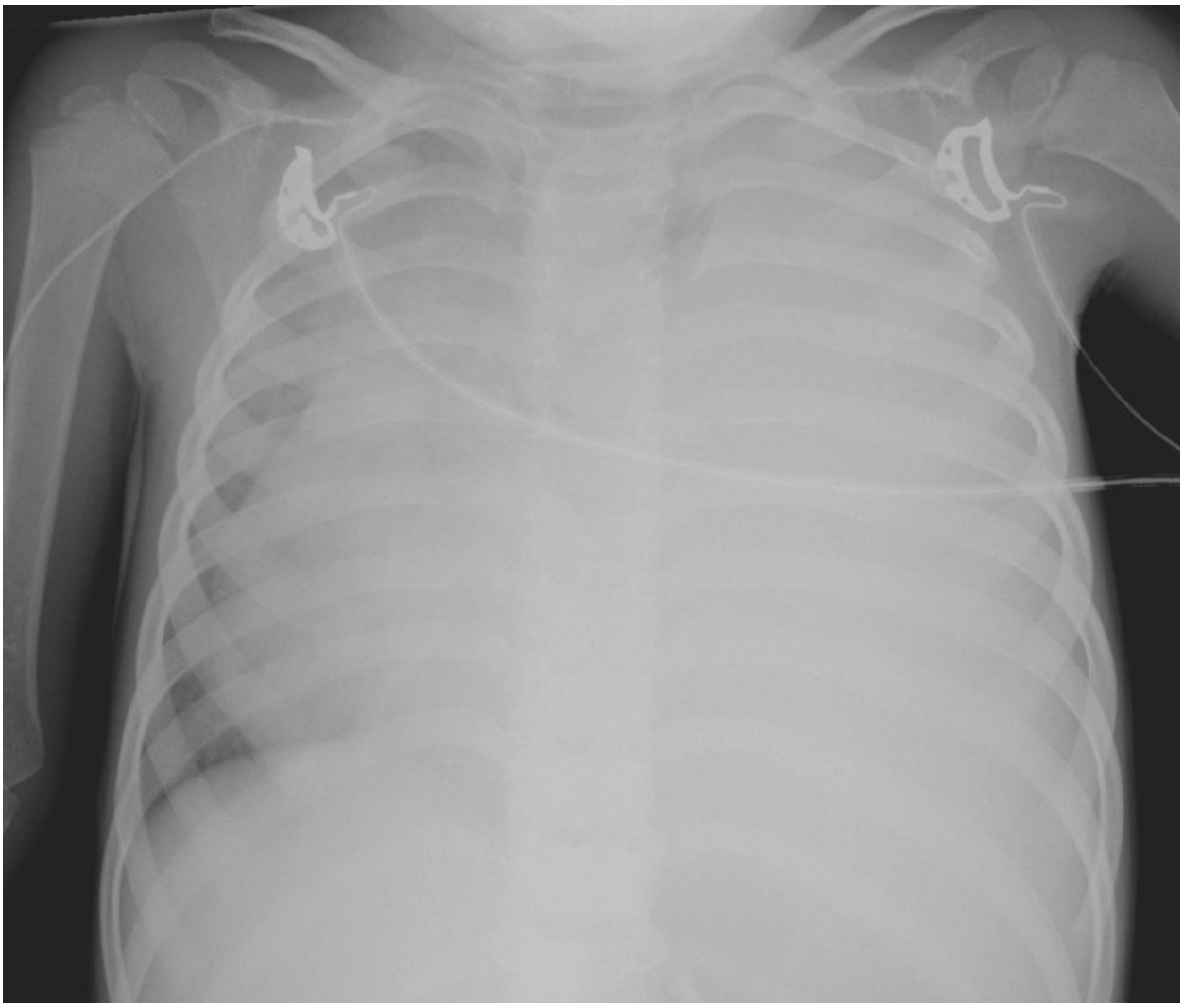

Fig. 34: Chest radiography PA view - 7 year-old male patient with progressive dyspnea. Notice the marked deviation of the mediastinum and heart to the right due to a large mass that occupies the entire left hemithorax.
References: Centro Hospitalar e Universitário de Coimbra - Hospital Pediátrico

Fig. 35: CT axial image of the thorax - Same patient as above. There is an heterogeneous enhancing mass that the deviates the heart and mediastinal structures, with an unclear point of origin. The patient underwent surgery and was diagnosed with a diaphragmatic rhabdomyosarcoma.
References: Centro Hospitalar e Universitário de Coimbra - Hospital Pediátrico

SECONDARY TUMORS

Metastatic involvement of the diaphragm is quite rare, with few reports in the literature. It is usually seen in disseminated disease and can occur either by hematogenic spread or direct invasion. The most frequent metastatic implants are secondary to head and neck tumors, lung tumors and less frequently to colorectal cancer, melanoma and breast cancers. Neurogenic tumors have also been described, and tend to involve the retrocrural space and diaphgramatic crura.

Fig. 36: CT axial image - 70 year-old male patient with complaints of abdominal pain. There is a large heterogeneous mass after contrast enhancement, predominantly hipodense with peripheral areas of vascularization, with unclear point of origin.
References: Radiology, Centro Hospitalar e Universitario de Coimbra, Hospital Geral - Coimbra/PT

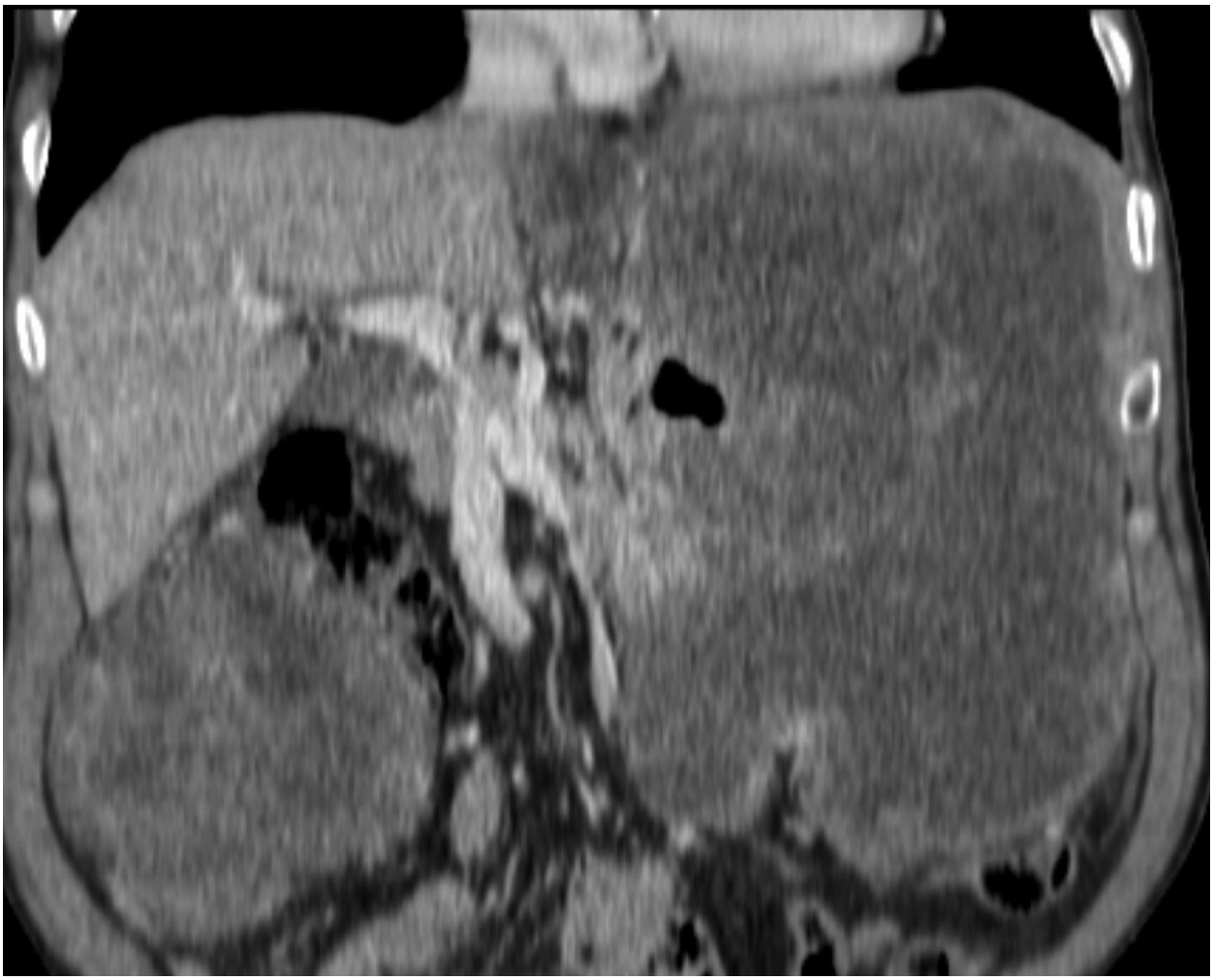

Fig. 37: CT coronal image - Same image as above. This mass seems to arise from the stomach, which has lost its normal morphology, and has a synchronous mass on the right flank. The patient underwent surgery and pathology revealed this was a gastric GIST with diaphgramatic infiltration.
References: Radiology, Centro Hospitalar e Universitario de Coimbra, Hospital Geral - Coimbra/PT

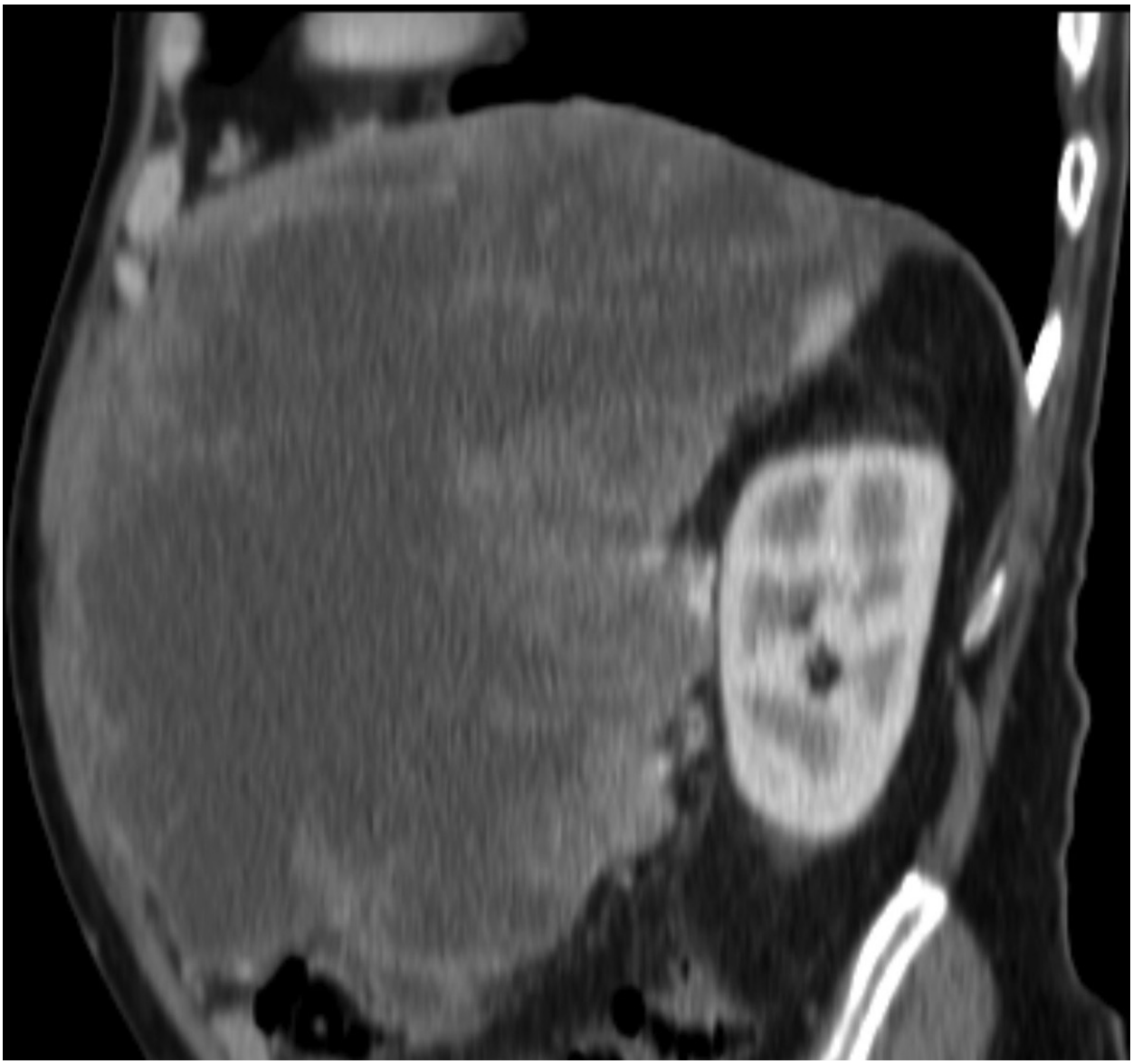

Fig. 38: CT sagital image - Same patient as above. Notice that there is no clear fat plane between the mass and the ipsilateral diaphragmatic leaflet, which shows some degree of thickening in its anterior portion.
References: Radiology, Centro Hospitalar e Universitario de Coimbra, Hospital Geral - Coimbra/PT

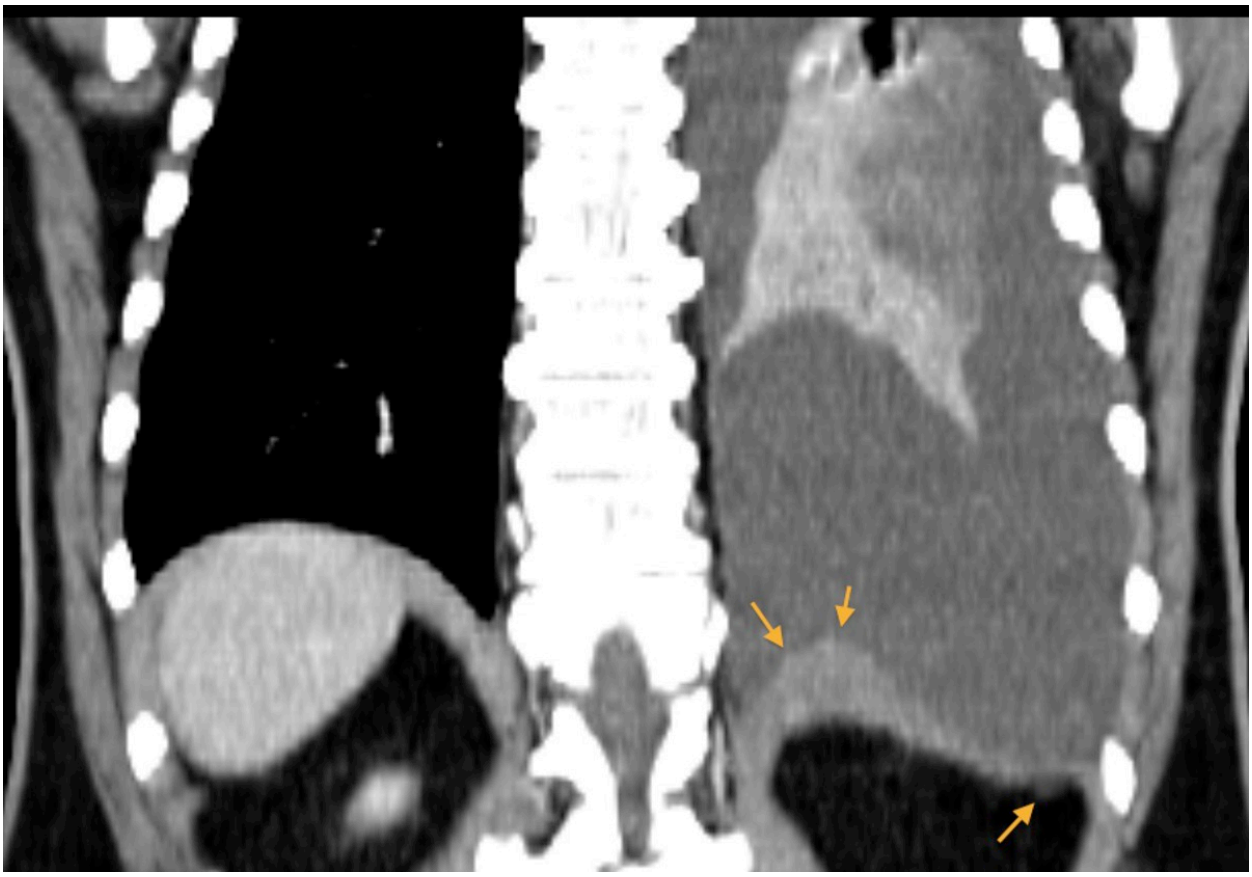

Fig. 39: Thorax CT coronal image - 52 year-old female with metastatic melanoma. There is thickening of the left diaphragmatic leaflet and there are metastatic implants in the abdominal surface.
References: Radiology, Centro Hospitalar e Universitario de Coimbra, Hospital Geral - Coimbra/PT

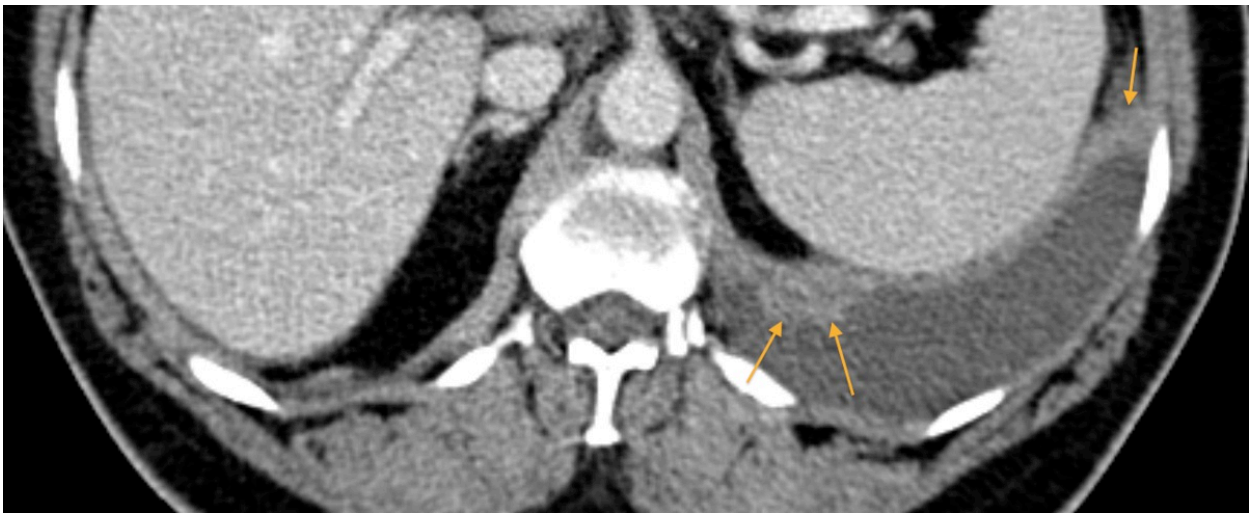

Fig. 40: CT axial image - Same patient as above. This image better depicts the metastatic implants, both in the thoracic and abdominal surfaces of the left hemidiaphragm.
References: Radiology, Centro Hospitalar e Universitario de Coimbra, Hospital Geral - Coimbra/PT

DIAPHRAGMATIC TRAUMA

Fig. 41
References: Radiology, Centro Hospitalar e Universitario de Coimbra, Hospital Geral - Coimbra/PT
Diaphragmatic tears are uncommon and usually occur secondarily to high impact, being associated with other severe injuries, such as splenic and renal trauma, in 81% of cases.

Diaphragmatic tears are more frequent on the **left,** due to presence of the liver on the right. Nevertheless, delayed presentation of tears on the right can lead to life threatning conditions such as bowel herniation and strangulation.

On chest radiography, specific findings of **diaphragmatic tear** include intrathoracic hollow viscus herniation at the site of tear and nasogastric tube above the left hemidiaphragm. Findings suggestive of **rupture** include hemidiaphragmatic elevation, distortion or obliteration of the normal contours.

CT is the modality of choice, with MPR reformats allowing for high sensitivy and specificity of 78% and 100% in left tears, and as much as 71% and 100% on right-sided tears. Some signs of diaphragmatic tear seen with CT are shown on table 2 (Fig.17)

Fig. 42: Thorax CT coronal image - 44 year-old male involved in a high impact vehicle collision. There is a tear on the left hemidiaphragm, and partial herniation of the stomach, which is adjacent to the left ventricle.
References: Radiology, Centro Hospitalar e Universitario de Coimbra, Hospital Geral - Coimbra/PT

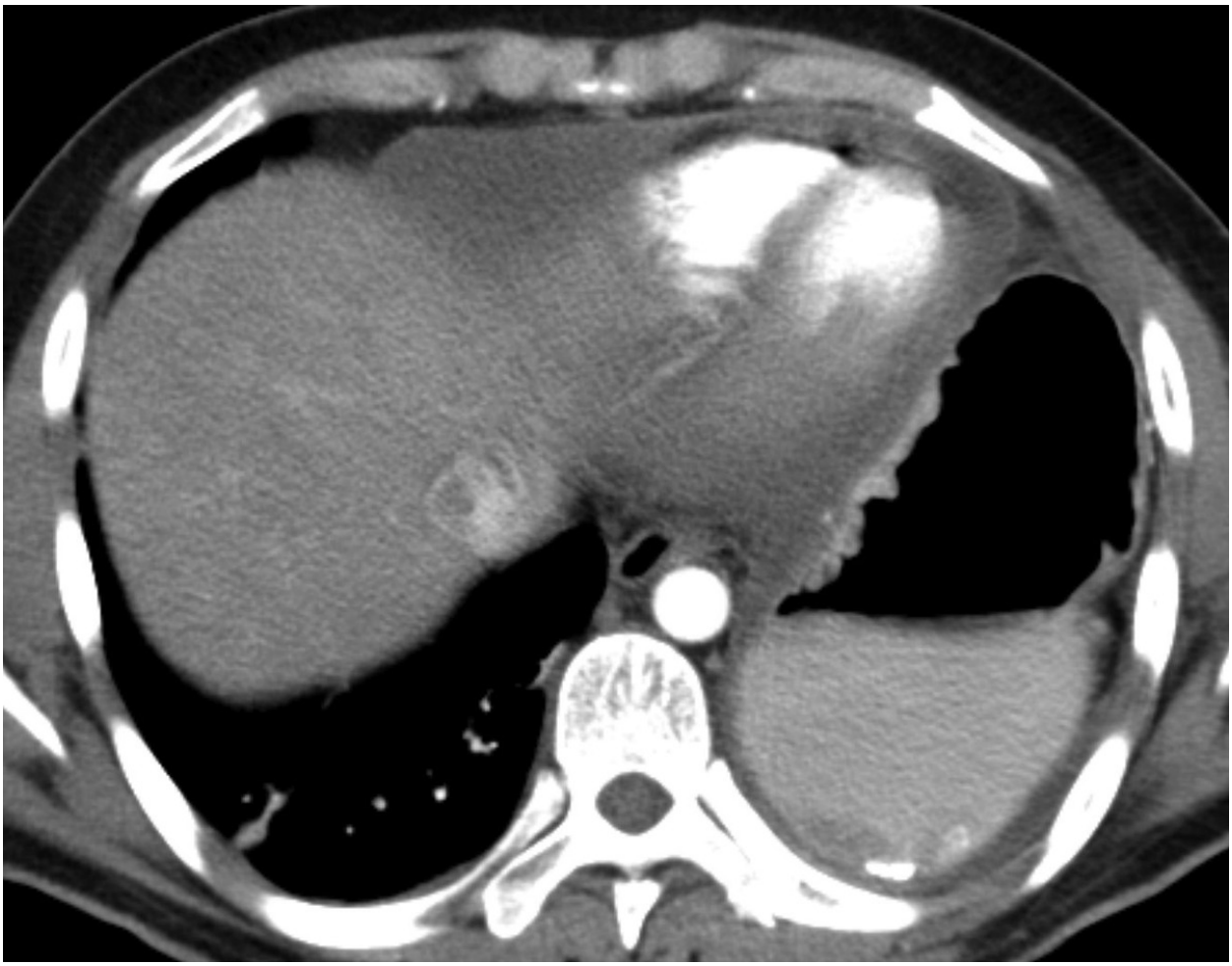

Fig. 43: CT axial image - Same patient as above. There is complete loss of the normal contours of the left diaphgram, indicating left tear which was later confirmed at surgery. ***References:*** Radiology, Centro Hospitalar e Universitario de Coimbra, Hospital Geral - Coimbra/PT

Images for this section:

CNS dysfunction

- Spinal cord injury, transverse myelitis, syrinx, tumors

PNS dysfunction

- Phrenic nerve dysfunction and neuropathies (Lyme's disease, Guillain-Barré)

Disorders of the neuromuscular transmission

- Miastenia Gravis, Lambert-Eaton syndrome

Myopathies

- Muscular dystrophies (Duchenne, Becker), metabolic or immunologic disorders

Fig. 16: Table PW - This table includes some of the most frequent causes of diaphragmatic paralysis or weakness

CT Signs of Diaphragmatic Injury

CT Sign	Description
Direct discontinuity of the hemidiaphragm	-
Intrathoracic herniation of abdominal contents	The stomach and colon on the left, and liver on the right
Collar sign	A waistlike constriction of the herniated viscera at the site of tear
Curled diaphragm sign	Irregularity and thickening of the hemiadiaphragm, secondarily to the torn muscle

Fig. 17: Table 2 - CT signs of diaphgramatic injury

Conclusion

The diaphragm is an important ventilatory muscle and its impairment or dysfunction can be a cause of dyspnea.

Diaphragmatic dysfunction can arise from a multitude of entities, the most frequent being surgery, followed by congenital disorders and trauma, but not forgetting tumors, either primary or secondary.

The most easily recognizable sign of impairment is its elevation, which can be seen with chest radiography. Nevertheless, conventional exams are seldomly sufficient for an accurate assessment of underlying conditions, which is why CT also plays an important part in this evaluation.

CENTRO HOSPITALAR E UNIVERSITÁRIO DE COIMBRA
FACULDADE DE MEDICINA DA UNIVERSIDADE DE COIMBRA

Fig. 44
References: Radiology, Centro Hospitalar e Universitario de Coimbra, Hospital Geral - Coimbra/PT

Personal information

Isabel Candelária

2nd year Radiology resident at Centro Hospitalar e Universitário de Coimbra - Serviço de Imagem Médica

References

Nason, L., Walker, C., McNeeley, M., Burivong, W., Fligner, C., Godwin, D., Imaging of the Diaphragm: Anatomy and Function, RadioGraphics, 2012, 32: 51-72

Sandstrom, C., Stern, E., Diaphragmatic Hernias: a spectrum of radiographic appearances, 2011, Current Problems in Diagnostic Radiology, 40(3): 95-115

Chavhan, G., Babyn, P., Cohen, R., Langer, J., Multimodality Imaging of the Pediatric Diaphragm: Anatomy and Pathologic Conditions, RadioGraphics, 2010, 30: 1797-1817

Restrepo, C., Eraso, A., Ocazionez, D., The Diaphragmatic crura and retrocrural space: normal imaging appearance, variants and pathologic conditions, RadioGraphics, 2008, 28(5): 1289-305